
Residual bed thickness and corneal forward shift after laser in situ keratomileusis

Kazunori Miyata, MD, Tadatoshi Tokunaga, COT, Masaaki Nakahara, MD, Shinichiro Ohtani, MD, Ryohei Nejima, MD, Takahiro Kiuchi, MD, Yuichi Kaji, MD, Tetsuro Oshika, MD

Purpose: To prospectively assess the forward shift of the cornea after laser in situ keratomileusis (LASIK) in relation to the residual corneal bed thickness.

Setting: Miyata Eye Hospital, Miyazaki, Japan.

Methods: Laser in situ keratomileusis was performed in 164 eyes of 85 patients with a mean myopic refractive error of -5.6 diopters (D) \pm 2.8 (SD) (range -1.25 to -14.5 D). Corneal topography of the posterior corneal surface was obtained using a scanning-slit topography system before and 1 month after surgery. Similar measurements were performed in 20 eyes of 10 normal subjects at an interval of 1 month. The amount of anteroposterior movement of the posterior corneal surface was determined. Multiple regression analysis was used to assess the factors that affected the forward shift of the corneal back surface.

Results: The mean residual corneal bed thickness after laser ablation was 388.0 ± 35.9 μm (range 308 to 489 μm). After surgery, the posterior corneal surface showed a mean forward shift of 46.4 ± 27.9 μm , which was significantly larger than the absolute difference of 2 measurements obtained in normal subjects, 2.6 ± 5.7 μm ($P < .0001$, Student *t* test). Variables relevant to the forward shift of the corneal posterior surface were, in order of magnitude of influence, the amount of laser ablation (partial regression coefficient $B = 0.736$, $P < .0001$) and the preoperative corneal thickness ($B = -0.198$, $P < .0001$). The residual corneal bed thickness was not relevant to the forward shift of the cornea.

Conclusions: Even if a residual corneal bed of 300 μm or thicker is preserved, anterior bulging of the cornea after LASIK can occur. Eyes with thin corneas and high myopia requiring greater laser ablation are more predisposed to an anterior shift of the cornea.

J Cataract Refract Surg 2004; 30:1067–1072 © 2004 ASCRS and ESCRS

Despite the overall success of laser in situ keratomileusis (LASIK), several problems remain. There is a concern that the biomechanical strength of the post-LASIK cornea is diminished by the surgical tissue subtraction and the intersection of Bowman's membrane.¹ Several cases of iatrogenic keratectasia after excimer laser

surgery have been documented.^{2–15} In a series of patients having LASIK, forward shift of the posterior corneal surface has been demonstrated.^{16,17} Increases in posterior corneal curvature resulting from anterior bulging of the cornea after photorefractive keratectomy (PRK)^{18,19} and LASIK²⁰ have also been reported, indicating that mild protrusion of the cornea is common early after excimer laser keratorefractive surgery.²⁰ There is anecdotal discussion that the flap does not contribute to the biomechanical stability of the cornea after it is repositioned on the stromal bed, and therefore the residual corneal bed thickness is a crucial factor in preventing subsequent iatrogenic keratectasia in LASIK.

Accepted for publication August 29, 2003.

Reprint requests to Tetsuro Oshika, MD, Department of Ophthalmology, Institute of Clinical Medicine, University of Tsukuba, 1-1-1 Ten-noudai, Tsukuba, Ibaraki, 305-8575 Japan. E-mail: toshika@md.tsukuba.ac.jp.

Wang and coauthors¹⁶ assessed 32 eyes of 16 patients after LASIK and reported that the mean bulge of the cornea is significantly larger in eyes with a residual bed thinner than 250 μm than in eyes with a residual bed of 250 μm or thicker. Except for this small study, however, the relationship between residual bed thickness and postoperative forward shift of the cornea has not been investigated. We conducted a prospective study to investigate the amount of forward shift of the cornea after LASIK in relation to the residual corneal bed thickness, preoperative corneal thickness, amount of myopic correction, intraocular pressure (IOP), and amount of laser ablation.

Patients and Methods

One hundred sixty-four eyes of 85 patients having LASIK for myopia were included in this study. Eyes with keratoconus were excluded using the keratoconus screening test of Placido disk videokeratography (TMS-2, Computed Anatomy Inc.). The patients were consecutive cases operated on between April and December 2001 at Miyata Eye Hospital. All patients signed an informed consent before the prospective study.

All surgery was performed by the same surgeon (K.M.) using the Vixx Star S2 excimer laser system. Laser parameters included the following: wavelength, 193 nm; radiant exposure (fluence), 160 mJ/cm²; pulse repetition rate, 10 Hz; mean ablation depth per pulse, 0.23 μm on the cornea; ablation zone diameter, 6.0 mm; transition zone, 0.35 mm; aspiration air flow was used for debris removal. An automated microkeratome (MK-2000, Nidek Ltd.) was used to create a hinged corneal flap of 160 μm thickness. In all eyes, the preoperative manifest refraction was selected as the target correction. During surgery, the corneal bed thickness was measured after the excimer laser ablation was completed using an ultrasound pachymeter (Altair, Optikon 2000).

Anterior and posterior corneal elevation and corneal thickness were measured with scanning-slit topography (Orbscan II, Bausch & Lomb) before and 1 month after surgery. Changes in the elevation of the posterior corneal surface were

evaluated at the center of the difference map generated from preoperative and postoperative elevation maps. For surface alignment in the difference map, the 3.0 mm wide peripheral annular fit zone was used.^{16,17}

In 20 eyes of 10 normal subjects (mean age 32.6 years \pm 5.3 [SD]), scanning-slit topography was measured twice at an interval of 1 month. The mean refraction in these eyes was -1.51 ± 0.89 D. The subjects had no ocular disease except mild refractive errors. The anteroposterior shift of the posterior corneal surface was similarly estimated, and the absolute values in the 20 eyes were averaged.

Stepwise multiple regression analysis was performed to investigate the relationship between several variables and the amount of forward shift of the posterior corneal surface after surgery. The preoperative and surgical variables studied included patient age and sex, preoperative IOP, preoperative refraction, preoperative corneal thickness, preoperative and postoperative keratometry values, amount of laser ablation (changes in corneal thickness), achieved myopic correction (refraction), and residual corneal bed thickness.

Results

The mean age of the 41 men and 44 women was 33.2 ± 9.3 years (range 19 to 52 years). The mean refraction was -5.6 ± 2.8 diopters (D) (range -1.5 to -14.0 D) before surgery and -0.08 ± 0.47 D 1 month after surgery ($P < .0001$, paired t test). Keratometry values were 43.95 ± 1.48 D before and 38.42 ± 2.48 D after surgery ($P < .0001$).

The mean residual corneal bed thickness after laser ablation was 388.0 ± 35.9 μm (range 308 to 489 μm). No cornea had a residual bed of 300 μm or thinner. After surgery, the posterior corneal surface displayed a mean forward shift of 46.4 ± 27.9 μm , which was significantly larger than the absolute difference between 2 measurements obtained in the normal subjects, 2.6 ± 5.7 μm ($P < .0001$, Student t test). No case had clinically apparent iatrogenic keratectasia.

Results of multiple regression analysis are shown in Table 1. Variables that were relevant to the forward

Table 1. Results of stepwise multiple regression analysis to select variables relevant to forward shift of the posterior corneal surface after LASIK.

Variable	Partial Regression Coefficient	Standardized Partial Regression Coefficient	P Value
Laser ablation (μm)	0.736	0.700	<.0001
Preoperative corneal thickness (μm)	-0.198	-0.224	<.0001
Constant	112.08	—	—

Adjusted $R^2 = 0.502$

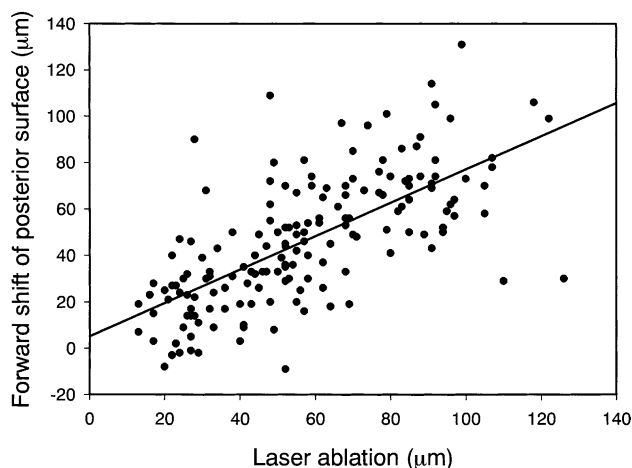


Figure 1. (Miyata) A significant positive correlation is shown between the amount of laser ablation and the forward shift of the posterior corneal surface ($r = 0.676$, Pearson correlation coefficient; $P < .001$).

shift of the corneal posterior surface were the amount of laser ablation and the preoperative corneal thickness. Since the preoperative refraction and the amount of achieved myopic correction showed multicollinearity with other variables, these parameters were not entered in the regression model. The residual corneal bed thickness was not relevant to the forward shift of the corneal posterior surface. The multiple regression equation was expressed as

$$\begin{aligned} \text{Forward shift of posterior surface } (\mu\text{m}) = & \\ & (0.736 \times \text{laser ablation}) + \\ & (-0.198 \times \text{preoperative corneal thickness}) + 112.08 \end{aligned}$$

Standardized partial regression coefficients were assessed to discern the magnitude of each variable's influence. As shown in Table 1, amount of laser ablation was the most relevant variable, followed by preoperative corneal thickness. Relationships between the variables and the amount of corneal forward shift are shown in Figures 1 and 2. The correlation between residual corneal bed thickness and forward shift of the posterior corneal surface was not significant even by the simple correlation test ($r = -0.123$, Pearson correlation coefficient; $P = .116$) (Figure 3).

Discussion

The influence of excimer keratorefractive surgery on the posterior corneal surface has been evaluated using

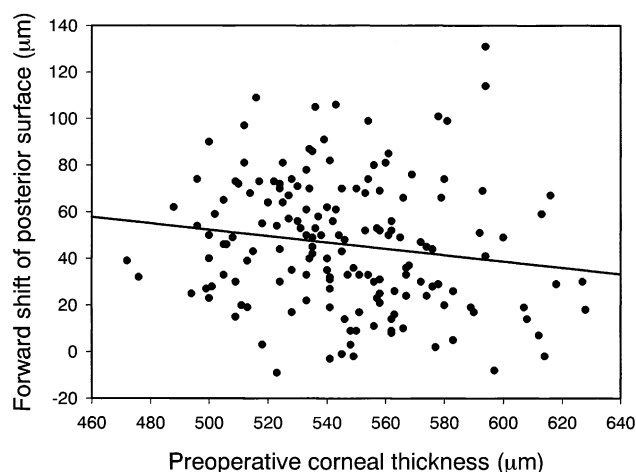


Figure 2. (Miyata) A significant negative correlation is shown between the preoperative corneal thickness and the forward shift of the posterior corneal surface ($r = -0.155$, Pearson correlation coefficient; $P < 0.05$).

scanning-slit corneal topography. On a difference map generated from the preoperative and postoperative posterior elevation maps, forward shift of the cornea after excimer laser surgery has been demonstrated.^{16-18,21} Steepening of the posterior corneal surface and increases in the negative posterior corneal power have also been revealed after PRK^{18,19} and LASIK.²⁰ Hernández-Quintela et al.²² report that refractive surgery did not induce significant changes in the radius of curvature of the posterior best-fit sphere, suggesting the limitation of scanning-slit topography measurements. The radius of curvature of the posterior best-fit sphere, however, is

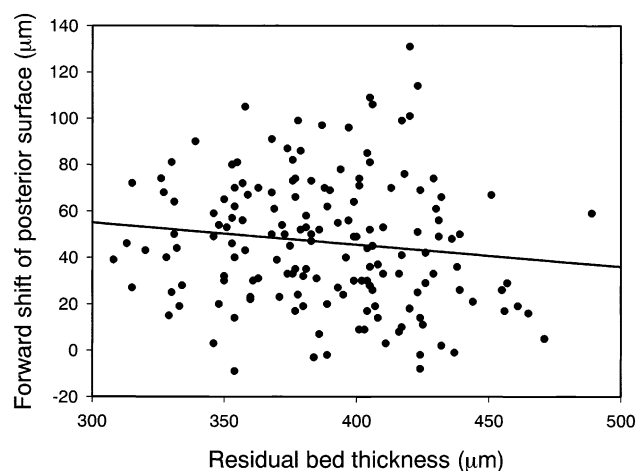


Figure 3. (Miyata) Relationship between the residual corneal bed thickness and the forward shift of the posterior corneal surface is shown. The correlation was not statistically significant ($r = -0.123$, Pearson correlation coefficient; $P = 0.116$).

not equivalent to the radius of curvature in the center of the posterior corneal surface nor does it exactly parallel the amount of anterior shift of the posterior corneal surface. The central cornea can be above or below the best-fit sphere, and thus the radius of curvature of the best-fit sphere does not represent the curvature or elevation of the central cornea. The best-fit sphere is used to facilitate color-coded presentation of the corneal height maps and is not the measure to assess the geometric and/or refractive changes in the central part of the corneal back surface.

We performed stepwise multiple regression analysis to investigate the relationship between various variables and the amount of forward shift of the posterior corneal surface after LASIK. Variables that were found to be relevant were the amount of laser ablation and the preoperative corneal thickness. Baek et al.¹⁷ also report that eyes with thin corneas and high myopia requiring greater laser ablation are more predisposed to an anterior shift of the cornea after LASIK. In a study that assessed the time course of changes in corneal forward shift after excimer laser PRK, Miyata et al.²¹ show that progression of a forward shift was more prominent in eyes with less preoperative corneal thickness and high myopia that required larger laser ablation. Judging from our study and previous studies, the preoperative corneal thickness and the amount of tissue subtraction by laser are the key factors that influence the tensile strength of the cornea after excimer laser keratorefractive surgery.

A previous study suggests a negative correlation between the residual corneal bed thickness and the forward shift of the posterior corneal surface.¹⁷ In that study, however, the actual bed thickness was not measured and the residual bed thickness was estimated, assuming that 160 μm thick corneal flaps had been created in all cases. The actual flap thickness is known to vary considerably and generally be thinner than intended.^{23–25} In the present study, we measured the bed thickness directly after laser ablation was completed during surgery.

As shown in the results, the residual corneal thickness was not entered in the multiple regression model. The correlation between residual corneal bed thickness and forward shift of the posterior corneal surface was not significant even by the Pearson correlation test, indicating that residual bed thickness is not relevant to

the anterior protrusion of the cornea after LASIK. There is a contention that at least 250 μm of central posterior stromal tissue should be preserved to maintain long-term corneal integrity and avoid postoperative corneal ectasia after LASIK.²⁶ Wang and coauthors¹⁶ report that the mean bulge of the cornea is significantly larger in eyes with a residual bed thinner than 250 μm than in those with a residual bed of 250 μm or thicker.

In our study population, at least 300 μm of corneal bed was preserved in each case. There are 2 possible interpretations of these results. First, if a residual corneal bed of 300 μm or thicker is preserved, the thinness of the residual bed is not a risk factor in the anterior protrusion of the cornea. Second, even in eyes in which the residual bed thickness is more than 300 μm , forward shift of the cornea is induced by LASIK. The degree of the forward shift is dependent on the preoperative corneal thickness and the amount of laser ablation.

At present, it is not clear whether the corneal forward shift observed in our study is progressive and some of the eyes will eventually develop keratectasia. Iatrogenic keratectasia is a potentially severe complication occurring in structurally compromised eyes after refractive surgery not only by an excimer laser procedure^{2–15} but also by repeated keratotomy surgery^{27,28} and deep primary keratotomy without laser application.²⁹ A 1-year follow-up study of PRK demonstrates that the largest forward shift occurs within the first postoperative week. Changes are progressive up to 6 months postoperatively but become almost stable thereafter.²¹ A similar long-term and large-scale study is needed for LASIK.

The limitation of scanning-slit corneal topography in measuring eyes after excimer laser keratorefractive surgery has been discussed, especially the accuracy of pachymetry in eyes after refractive surgery. In normal eyes, corneal thickness measurements of scanning-slit corneal topography, corrected with the acoustic equivalent factor (0.92), are similar to those of ultrasonic pachymetry.^{30,31} In eyes that have had excimer laser keratorefractive surgery, however, Orbscan II scanning-slit topography has been reported to significantly underestimate corneal thickness compared to ultrasonic pachymetry.^{32,33} The presence of corneal haze further contributes to the artifactually reduced pachymetry.^{30,34} Scanning-slit topography/pachymetry measures the corneal thickness by subtracting points on the posterior

surface from those on the anterior surface. In light of significant underestimation of corneal thickness by Orbscan pachymetry in post-LASIK eyes, there is a possibility that posterior corneal elevation is not accurately measured in these eyes. It should be pointed out that the current results might be partially artifactual since no direct measurement of the posterior corneal elevation is available. The accuracy of Orbscan II anterior surface elevation measurements has been confirmed in test objects³⁵; similar tests have not been conducted on the precision of posterior surface elevation measurements. Elucidation of these points awaits further studies.

References

- Müller LJ, Pels E, Vrensen GFJM. The specific architecture of the anterior stroma accounts for maintenance of corneal curvature. *Br J Ophthalmol* 2001; 85:437–443
- Shimmura S, Yang H-Y, Bissen-Miyajima H, et al. Posterior corneal protrusion after PRK. *Cornea* 1997; 16:686–688
- Seiler T, Koufala K, Richter G. Iatrogenic keratectasia after laser in situ keratomileusis. *J Refract Surg* 1998; 14:312–317
- Seiler T, Quurke AW. Iatrogenic keratectasia after LASIK in a case of forme fruste keratoconus. *J Cataract Refract Surg* 1998; 24:1007–1009
- Geggel HS, Talley AR. Delayed onset keratectasia following laser in situ keratomileusis. *J Cataract Refract Surg* 1999; 25:582–586
- Schmitt-Bernard C-F-M, Lesage C, Arnaud B. Keratectasia induced by laser in situ keratomileusis in keratoconus. *J Refract Surg* 2000; 16:368–370
- Özdamar A, Aras C, Ustundag C, et al. Corneal iron ring associated with iatrogenic keratectasia after myopic laser in situ keratomileusis. *J Cataract Refract Surg* 2000; 26:1684–1686
- Amoils SP, Deist MB, Gous P, Amoils PM. Iatrogenic keratectasia after laser in situ keratomileusis for less than -4.0 to -7.0 diopters of myopia. *J Cataract Refract Surg* 2000; 26:967–977
- Joo C-K, Kim T-G. Corneal ectasia detected after laser in situ keratomileusis for correction of less than -12 diopters of myopia. *J Cataract Refract Surg* 2000; 26:292–295
- Miyata K, Takahashi T, Tomidokoro A, et al. Iatrogenic keratectasia after phototherapeutic keratectomy [letter]. *Br J Ophthalmol* 2001; 85:247–248
- Lafond G, Bazin R, Lajoie C. Bilateral severe keratoconus after laser in situ keratomileusis in a patient with forme fruste keratoconus. *J Cataract Refract Surg* 2001; 27:1115–1118
- Eggink FAGJ, Beekhuis WH. Contact lens fitting in a patient with keratectasia after laser in situ keratomileusis. *J Cataract Refract Surg* 2001; 27:1119–1123
- Argento C, Cosentino MJ, Tytiun A, et al. Corneal ectasia after laser in situ keratomileusis. *J Cataract Refract Surg* 2001; 27:1440–1448
- Pallikaris IG, Kymionis GD, Astyrakakis NI. Corneal ectasia induced by laser in situ keratomileusis. *J Cataract Refract Surg* 2001; 27:1796–1802
- Rao SN, Epstein RJ. Early onset ectasia following laser in situ keratomileusis: case report and literature review. *J Refract Surg* 2002; 18:177–184
- Wang Z, Chen J, Yang B. Posterior corneal surface topographic changes after laser in situ keratomileusis are related to residual corneal bed thickness. *Ophthalmology* 1999; 106:406–409; discussion by RK Maloney, 409–410
- Baek TM, Lee KH, Kagaya F, et al. Factors affecting the forward shift of posterior corneal surface after laser in situ keratomileusis. *Ophthalmology* 2001; 108:317–320
- Kamiya K, Oshika T, Amano S, et al. Influence of excimer laser photorefractive keratectomy on the posterior corneal surface. *J Cataract Refract Surg* 2000; 26:867–871
- Naroo SA, Charman WN. Changes in posterior corneal curvature after photorefractive keratectomy. *J Cataract Refract Surg* 2000; 26:872–878
- Seitz B, Torres F, Langenbucher A, et al. Posterior corneal curvature changes after myopic laser in situ keratomileusis. *Ophthalmology* 2001; 108:666–672; discussion by ED Donnenfeld, 673
- Miyata K, Kamiya K, Takahashi T, et al. Time course of changes in corneal forward shift after excimer laser photorefractive keratectomy. *Arch Ophthalmol* 2002; 120:896–900
- Hernández-Quintela E, Samapunphong S, Khan BF, et al. Posterior corneal surface changes after refractive surgery. *Ophthalmology* 2001; 108:1415–1422
- Yi W-M, Joo C-K. Corneal flap thickness in laser in situ keratomileusis using an SCMD manual microkeratome. *J Cataract Refract Surg* 1999; 25:1087–1092
- Maldonado MJ, Ruiz-Oblitas L, Munuera JM, et al. Optical coherence tomography evaluation of the corneal cap and stromal bed features after laser in situ keratomileusis for high myopia and astigmatism. *Ophthalmology* 2000; 107:81–87; discussion by DR Hardten, 88
- Vesaluoma M, Pérez-Santonja J, Petroll WM, et al. Corneal stromal changes induced by myopic LASIK. *Invest Ophthalmol Vis Sci* 2000; 41:369–376; erratum, 2027
- Probst LE, Machat JJ. Mathematics of laser in situ keratomileusis for high myopia. *J Cataract Refract Surg* 1998; 24:190–195

27. Wellish KL, Glasgow BJ, Beltran F, Maloney RK. Corneal ectasia as a complication of repeated keratotomy surgery. *J Refract Corneal Surg* 1994; 10:360–364
28. Shaikh S, Shaikh NM, Manche E. Iatrogenic keratoconus as a complication of radial keratotomy. *J Cataract Refract Surg* 2002; 28:553–555
29. Haw WW, Manche EE. Iatrogenic keratectasia after a deep primary keratotomy during laser in situ keratomileusis. *Am J Ophthalmol* 2001; 132:920–921
30. Fakhry MA, Artola A, Belda JI, et al. Comparison of corneal pachymetry using ultrasound and Orbscan II. *J Cataract Refract Surg* 2002; 28:248–252
31. Suzuki S, Oshika T, Oki K, et al. Corneal thickness measurements: scanning-slit corneal topography and noncontact specular microscopy versus ultrasonic pachymetry. *J Cataract Refract Surg* 2003; 29:1313–1318
32. Iskander NG, Anderson Penno E, Peters NT, et al. Accuracy of Orbscan pachymetry measurements and DHG ultrasound pachymetry in primary laser in situ keratomileusis and LASIK enhancement procedures. *J Cataract Refract Surg* 2001; 27:681–685
33. Prisant O, Calderon N, Chastang P, et al. Reliability of pachymetric measurements using Orbscan after excimer refractive surgery. *Ophthalmology* 2003; 110:511–515
34. Boscia F, La Tegola MG, Alessio G, Sborgia C. Accuracy of Orbscan optical pachymetry in corneas with haze. *J Cataract Refract Surg* 2002; 28:253–258
35. Cairns G, McGhee CNJ, Collins MJ, et al. Accuracy of Orbscan II slit-scanning elevation topography. *J Cataract Refract Surg* 2002; 28:2181–2187

From the Miyata Eye Hospital (Miyata, Tokunaga, Nakahara, Ohtani, Nejima), Miyasaki, and the Department of Ophthalmology, Institute of Clinical Medicine, University of Tsukuba (Kiuchi, Kaji, Oshika), Ibaraki, Japan.

None of the authors has a proprietary interest in any material or method mentioned.